

Basic Guide to

Dermatologic

Photography

1 May 1999

BY *MAJ Hon S. PAK*
Dermatology
Walter Reed Army Medical Center
Washington DC 20307

Table of Contents

TOPIC	PAGE
I. Objective.....	3
II. Background.....	3
III. Required Materials.....	4
IV. Common Problems.....	4
V. Principles of Dermatologic Photography.....	5
VI. Lighting and Focusing.....	6
VII. Standardized Images.....	7
A. By Type and Extent of Involvement	
1. Algorithm.....	8
a. Single.....	9
b. Localized.....	9
c. Generalized.....	9
B. By Site or Location	
1. Total Body.....	10
2. Truncal.....	11
3. Head/ Neck.....	12
4. Extremities.....	13
5. Hands/Feet.....	14
6. Genitalia.....	15
VIII. Review.....	16
IX. Helpful Hints.....	17
X. Dress Code.....	18
XI. Summary.....	19

OBJECTIVE AND BACKGROUND

Objective: This is to serve as a basic guide for non-dermatologists on how to take basic clinical photographs in dermatology using a digital camera.

Background: A significant number of digital images in any new store and forward consult system will have some fundamental problems with the quality. In identifying some of these problems, we found that there is a real lack of an understanding of the fundamental concepts in dermatology. Dermatologists use certain clues to diagnose skin conditions; the goal of photography is to reproduce these clues or findings.

In fact, most dermatologic photography is currently taken by dermatologists who already have an idea of what the particular diagnosis is. The dermatologists have been trained and use all the visual clues to render a diagnosis. Thus, taking photographs is merely an attempt to capture the unique characteristics of the particular skin condition that the dermatologists see and recognize with their own eyes.

For the non-dermatologist who is not trained in the art of dermatology, it is difficult to capture the particular characteristics of the skin rash or lesion without understanding what they are looking for first. However, this is exactly what is required in teledermatology: a non-dermatologists must be trained first to be able to identify the extent of the skin condition. He or she must then attempt to reproduce the characteristic findings for the remote physician via still digital images so that a correct diagnosis can be rendered.

Good photographic techniques will yield good quality images, and by optimizing the quality of information on the images, we are attempting to maximize the diagnostic accuracy of the remote dermatologist.

REQUIRED MATERIALS AND COMMON PROBLEMS

Required Materials:

- Digital Camera with minimum of 800x600 resolution and a Macro capability with Zoom lens 35-105mm (35mm)equivalent.
- Storage Card or serial interface to PC
- PC
- Backdrop: 6'x3' non-reflectant surface light blue cloth
- Measurement tape.
- Skin Marker

Common problems:

1. Images not Focused- see Section on Focusing.
2. More or different views needed.(See Section on Standardized Images-Framing)
3. Poor resolution- Intrinsic property of the camera and not user dependent. There may be different resolution settings- use at least 800x600 resolutions.

PRINCIPLES OF DERMATOLOGIC PHOTOGRAPHY

Dermatologists use visual clues to make a diagnosis. The clues can be broken down into several categories:

VISUAL CLUES/CHARACTERISTICS:

Distribution (Location of the involved areas)

-Single, Acral, Sun-exposed area, Diffuse, unilateral, segmental, etc.

Configuration(Arrangement of lesions with respect to one another)

-Linear, Zosteriform, Annular, Nummular, Grouped, etc

Primary Lesion: (Represent the fundamental Lesion of the skin)

-Papule, Macule, Plaque, Vesicles.

Secondary Changes: (Represent overlying skin changes)

-Scale, crust, and keratoses.

By having a good understanding of these four visual clues/characteristics, we can now talk about what is required to reproduce these characteristics for each lesion or rash.

1. **Distribution** information is usually best portrayed using a Far-View image whether this is the whole body or just a body part such as a hand. Remember that this distant-view usually requires that the entire area involved including some uninvolved areas. In addition, unless it is a single lesion, including the contralateral views of the body gives information on symmetry in this far-view. For example, if there is a lesion or rash on one knee, the frame should include both knees and the surrounding uninvolved areas of the leg.

2. **Configuration** information is usually best portrayed using a medium-distance view as you are attempting to show any spatial relationship between the individual lesions if they exist. One should look for common configurations such as any linearity or annularity or other common configurations such as grouped lesions.

3. **Primary Lesions and Secondary Lesions** are best portrayed using a close up view in order to capture the most detail of the individual lesions along with any surface changes. This Macro or close up requires that a zoom lens is available or that the digital camera has to be physically close to the skin.

Most standard images should be taken at 90 degrees from the lesion of interest. However, in some cases, overlying skin changes may be subtle in which case an oblique view may be particularly helpful. It is optimal to place a small 10cm white/black tape ruler with mm markings next to the individual lesions to allow for approximation of size.

The area of interest should always be centered and marked(using an arrow or etc) on the skin if possible.

LIGHTING AND FOCUSING

Lighting

- Attempt to use a naturally well lit room. Try to avoid intense bright and direct light and avoid fluorescent light if possible.
- Use the camera's intrinsic flash in most situations. Do not use extra external light sources unless you are familiar with this technique and have gotten good consistent results. Always avoid the desire to get too close as the flash may be too much and cause a white-out.

Focusing

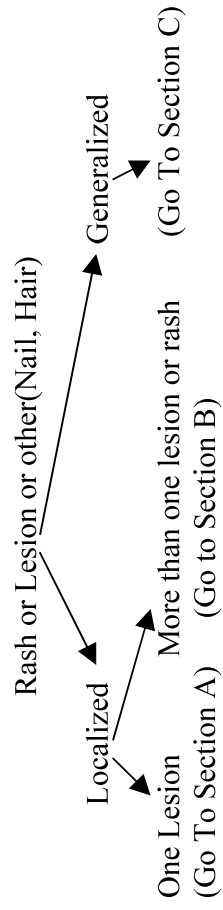
- Use Autofocus and place the area of interest in the center of the frame. If the center of the frame does not contain the area of interest, then focus first on the area of interest by depressing and holding the shutter $\frac{1}{2}$ way down with then while holding down the shutter button, move the camera to re-center the image.
- Use LCD to ensure that the picture is in focus prior to capturing image.
- Ensure that the macro selection button is selected only for close distances(e.g. 12" to 24")

STANDARDIZED IMAGES:

There are no true “standardized images” for dermatology, and it is very difficult to make a rigid set of rules or standards because of the complexity and the variability of the presentation of skin conditions. However, in this section, we will attempt to give some general guidelines which can be applied consistently to all skin conditions.

A simple algorithm for photographs as shown below should be used in order to streamline the process of taking proper and optimal pictures in dermatology.

Algorithm



See Next Page(9) to refer to Sections A,B,C

FRAMING IMAGE BY TYPE AND INVOLVEMENT OF SKIN LESION/RASH

Section A: Single Lesion (2-3 images)

1. *Medium View*:(1 image) The lesion should be in the center of the frame. Include some anatomical landmark(e.g. belly button or joint) to ensure that the location is obvious.
2. *Max Optical Zoom*(if available):(1-2 images) at the closest distance(usually 12” away from the lesion). Do not get much closer than 12”. Consider getting an oblique view.

Section B: Localized rash or Lesion > 1(3-4 images).

1. *Distant View*(1 image): Frame the rash or lesions so that the entire rash or lesions + ~25% of normal area are included within the image. Ensure that the location is obvious by ensuring that an anatomical location is obvious.
2. *Medium*(1 image): Look for configuration(linear, annular, circular lesions) If none, take a picture of a skin surface area of 2’ x 2’.
3. *Close Up*(1-2 images): Look for a representative lesion and take a close up image at the maximum optical zoom at the closest allowed distance(usu 12”). Consider getting an oblique view.

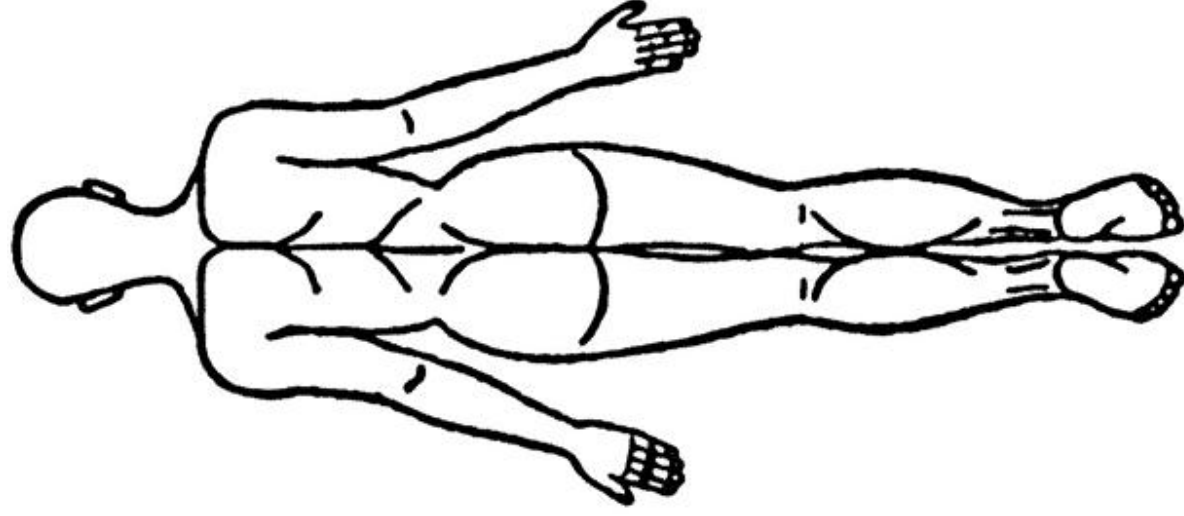
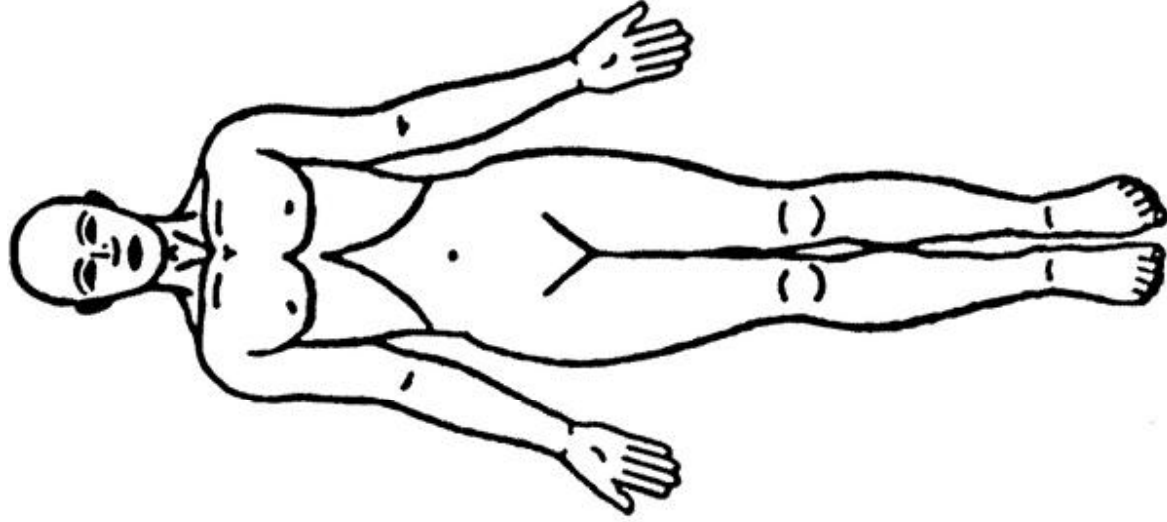
Section C: Generalized Rash(3-4 images)

1. *Distant View*(2 images): Frame the rash or lesions so that the entire rash or lesions + 20% of normal area are included within the image. This will be either a total body(head to toe) image or Truncal depending on the extent of involvement. If face/head and the distal arms and legs are not involved, take an image of the trunk and prox extremities in one frame- Front and Back. Head to Toe view in the proper anatomical position will be required – both front and back if face and trunk is involved.
2. *Medium*(1 image): Look for configuration(linear, annular, circular lesions) If none, take a picture of an area of 1 square foot.
3. *Close Up*(1 image): Look for a representative lesion and take a close up image at the maximum optical zoom at the closest allowed distance(usu 12”)


Framing Images by Location

- This section shows by location, how to frame the image of the involved body site. It is not all inclusive or exclusive. Another words, the frames shown include the recommended distant or medium view but does not show the close ups or the obliques. It is intended to show the ideal framing of the body part to show only distribution and symmetry.

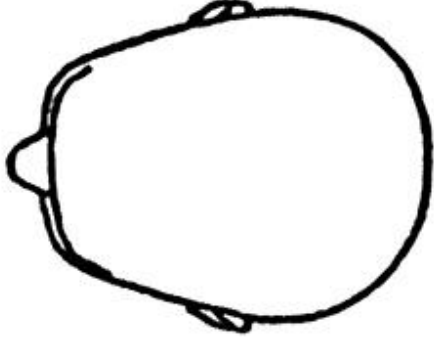
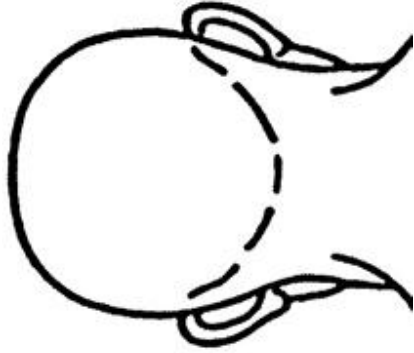
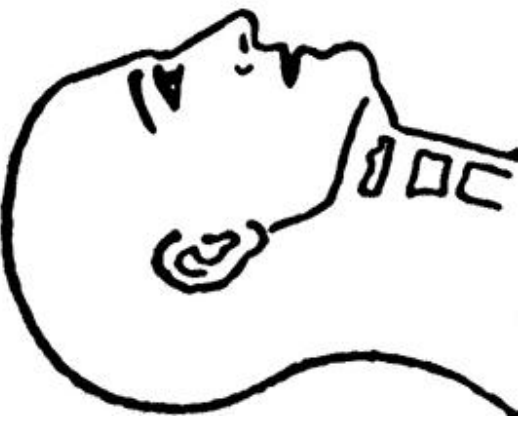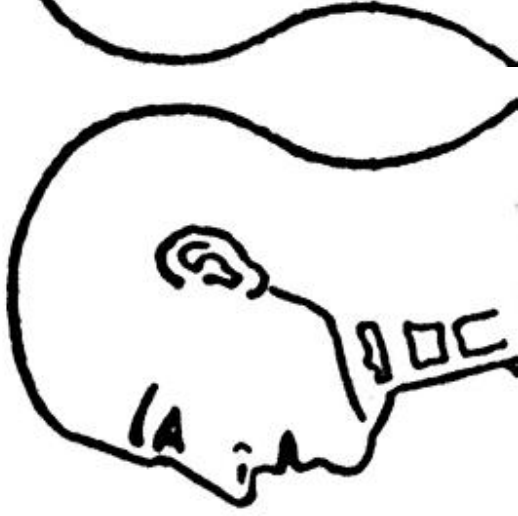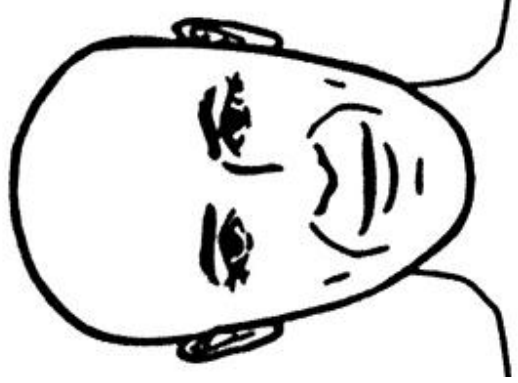
Generalized: Total Body (includes face and hands/feet)



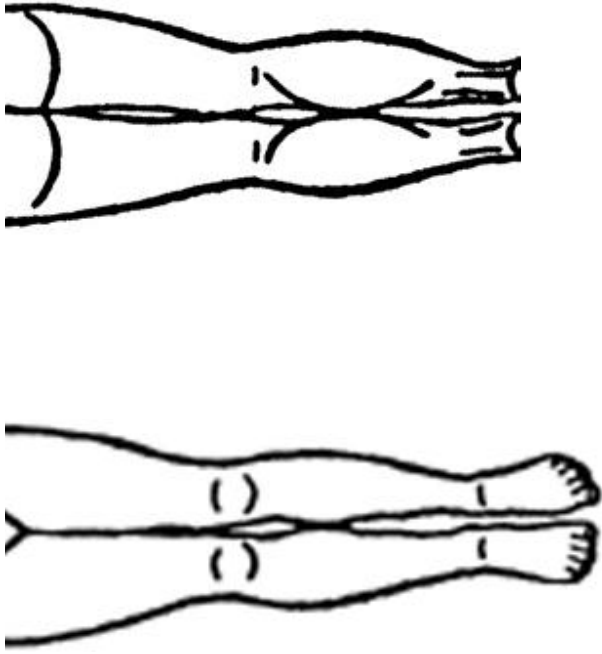
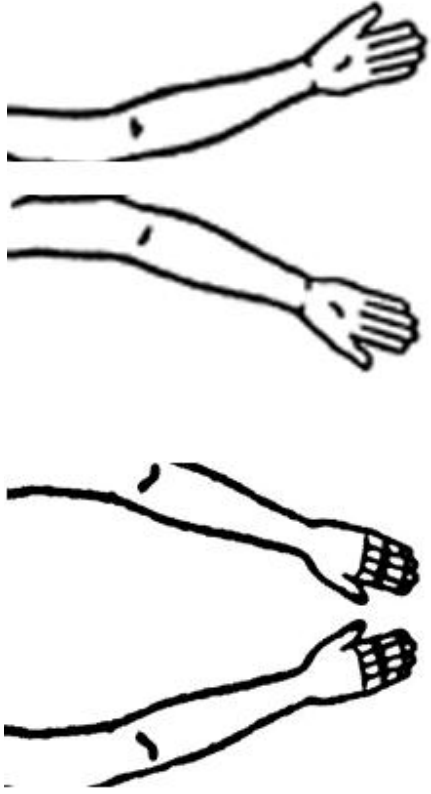
Generalized: Predominantly Trunk



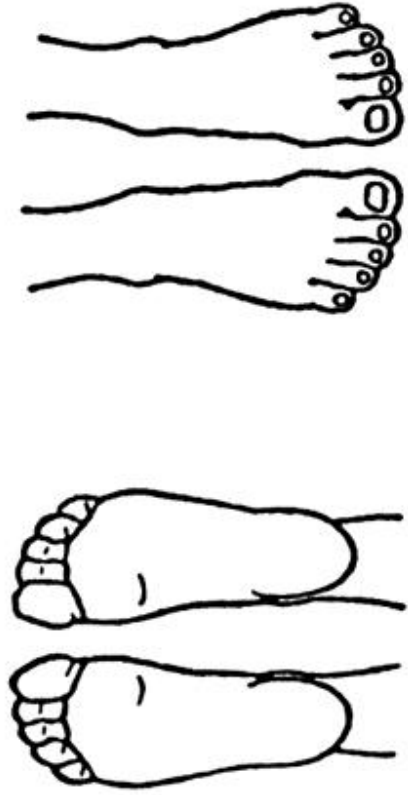
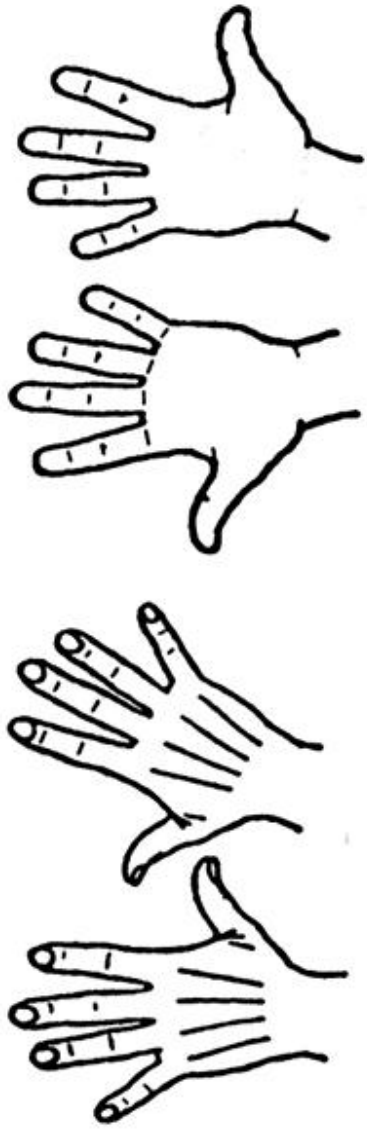
Head and Neck



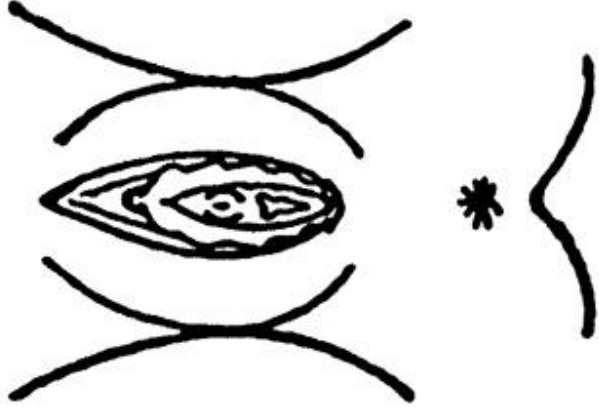
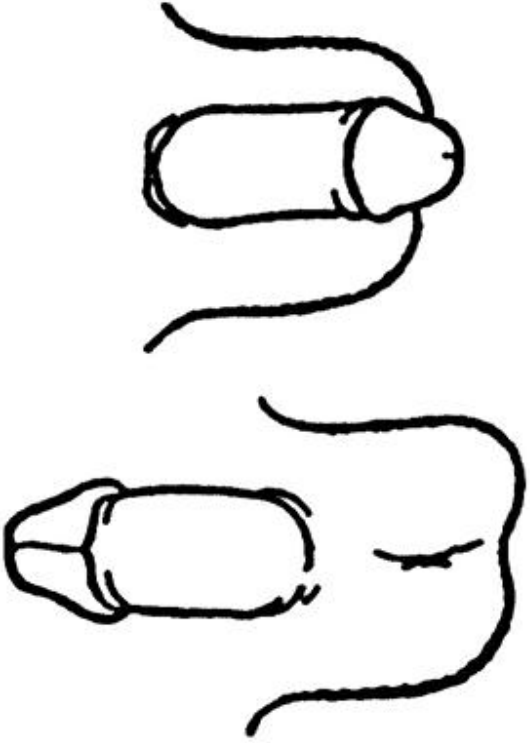
Extremities



Hands and Feet



Genitalia: Male and Female



REVIEW

The last step is the review to ensure that what is on the image is in fact what you wanted to capture.

1. First open the image file and view the captured image using a imaging software such as Adobe photoshop and ensure that the image is adequate.
2. Ensure that the location/anatomy is identifiable at least on one of the images
3. Ensure that the lesion of interest is centered, marked and focused. What may be obvious while taking the picture may not be so obvious on the image itself.
4. The Bottom Line: Ensure that the lesion(s) seen on the image(s) are representative of the actual lesions on the patient. If not, recapture the image.

HELPFUL TIPS

1. For Hair problems, ensure that you use the patient's hands or a comb/clip to lay the hair down to the side and ensure that the focus is on the scalp not the individual hairs. (Model shows how to hold the hair down)
2. Special Locations: If there is a rash on the hands or finger nails are involved, take a picture of both hands and feet.(Model shows image with all nails showing- finger and toenails) Both hands and feet images should include all ten fingers or toes in the same image.(Model shows image of both hands- front and back then another set with both feet top and bottom)
3. Symmetry: If there is a rash on one side of the face, body or extremity, be sure to include the opposite side in the picture. (Model show both arms together)
4. If the groin area is involved, have the patient expose the areas of interest using his/her own hands.(Model shows inguinal fold by exposing the area)
5. If either elbow or knee is involved, be sure to include all elbows and knees in the same frame.(Model shows image of knees and elbows showing in one view)
6. BACKGROUND: If possible, use a Backdrop for all photos: 6' x3' non-reflectant surface light blue cloth

DRESS CODE

For Males and females:

1. For a generalized rash, remove all clothing and jewelry except undergarments, unless those area are also involved. (Show model removing clothing and jewelry and final proper position)
2. For localized rash, remove only necessary clothing to allow adequate photography.
3. And of course, chaperones should be utilized appropriately.

SUMMARY

1. Utilize the algorithm to determine the number and types of views that will be needed.
2. Utilize the concepts of dermatology to capture the characteristics on the digital images.
3. Use the helpful hints to capture optimal images
4. In short, attempt to tell a story with your pictures from far to close-up.

Please remember that you play a critical role. The images that you send will determine whether or not the dermatologist will make a correct diagnosis.

Point of Contact:

Hon S. Pak
MAJ MC USA
Email- hpak@bethrad.med.navy.mil